

Randomised controlled trial of local allergoid immunotherapy on allergic inflammation in mite-induced rhinoconjunctivitis

Giovanni Passalacqua, Monica Albano, Laura Fregonese, Annamaria Riccio, Caterina Pronzato, Giuseppe Sandro Mela, Giorgio Walter Canonica

Summary

Background Non-injective routes of immunotherapy are thought to be valuable therapeutic options for respiratory allergy. We investigated the clinical efficacy and the effects of sublingual/oral immunotherapy on conjunctival allergic inflammation in patients with mite-induced respiratory allergy.

Methods We used a double-blind placebo-controlled design. 20 patients with mite-induced rhinoconjunctivitis (six of whom also had mild asthma) were randomly assigned sublingual/oral immunotherapy (n=10) or placebo (n=10) for 2 years. We assessed symptom score by diary cards and inflammatory-cell infiltrate, and expression of intercellular adhesion molecule 1 (ICAM-1) in the conjunctiva after specific allergen challenge at enrolment and after 12 and 24 months of treatment.

Findings We found significantly lower symptom scores in the immunotherapy group than in the placebo group in most of the winter months ($p=0.05$). Compared with the placebo group, inflammatory-cell infiltration after conjunctival challenge, and ICAM-1 expression on conjunctival epithelium decreased significantly in the first year of treatment in the immunotherapy group ($p=0.04$ and $p=0.02$, respectively). These effects were also seen for the minimum persistent inflammation, in symptom-free patients exposed constantly to allergens ($p=0.02$). Serum concentrations of eosinophil cationic protein decreased significantly ($p=0.04$). Immunotherapy was well tolerated and compliance was good.

Interpretation Our results suggest that this immunotherapy is clinically effective in rhinoconjunctivitis and that it decreases the immune-mediated inflammatory responses to the allergen.

Lancet 1998; **351**: 629–32

See Commentary page ?????

Introduction

In the past 15 years, interest has increased in Europe in local (non-injective) allergen-specific immunotherapy by oral, sublingual, nasal, and bronchial routes.¹ Improvement in safety and compliance has been aimed for.² WHO have accepted nasal and the sublingual immunotherapy as possible therapeutic options. Several controlled trials with restrictive criteria have shown sublingual immunotherapy to be effective.^{3–6} (The route is more properly defined as sublingual/oral.) Immediately swallowed, allergens without sublingual dissolution have given conflicting results, but some systemic immunological changes have been described.^{7–9} Observations on the tolerability of oral administration of antigens support the use of oral immunotherapy.¹⁰ In addition, we have shown previously the possible involvement of oral mucosal immunity in sublingual administration. Although we saw no direct absorption of the extract, the allergen stayed in the mouth for a long time after swallowing.¹¹ Therefore, effective oral administration should involve mucosal contact as well as ingestion of the extract.

Nasal and conjunctival allergen-specific challenges have been recognised as useful tools for the investigation of allergic inflammation.^{12,13} Allergenic challenge is followed by an early-phase reaction, which starts within 30 min, and a late-phase reaction, which occurs after about 6 h and slowly subsides. These reactions include a clinical response, a cellular infiltration, and the expression of intercellular adhesion molecule 1 (ICAM-1) on epithelial cells, which is specific and can be used as a reliable marker of the allergen-driven inflammation.^{12–14} Symptom-free allergic people who are exposed continuously to an allergen have a minimum persistent inflammation.¹⁴ These models enabled us to investigate the course of allergic inflammation, as described for nasal immunotherapy.¹⁵ Some mediators released by activated cells, such as eosinophil cationic protein and myeloperoxidase can be detected in peripheral blood and can also be useful for the monitoring of disease activity.

We investigated the clinical efficacy and the immunological effects of a sublingual/oral immunotherapy in patients with perennial rhinoconjunctivitis induced by house-dust mites, the most important indoor allergens. We focused on the allergen-induced immune inflammation before and after allergen-specific conjunctival challenge.¹²

Methods

We used a double-blind, placebo-controlled design. Before beginning the treatment (randomly coded before the study), there was a run-in period for all patients (January to March, 1994) during which we assessed them before treatment began. Treatment started in April, 1994, and continued until March, 1996, when the double-blind code was revealed. The study was approved by the ethical committee of the Department of Internal Medicine, Genoa University, Italy.

Allergy and Clinical Immunology Service (G Passalacqua MD, M Albano MD, L Fregonese MD, A Riccio BS, C Pronzato MD, G W Canonica MD) and **Laboratory of Clinic Informatics** (G S Mela MD), **DIMI, Department of Internal Medicine, Genoa University, Genoa, Italy**

Correspondence to: Dr Giorgio Walter Canonica, Allergy and Clinical Immunology Service, DIMI, Department of Internal Medicine, V le Benedetto XV 6, 16132 Genoa, Italy

	Treatment group	
	Active (n=10)	Placebo (n=10)
Median (range) age in years	25 (15–37)	27.2 (17–46)
Sex (M/F)	3/7	4/6
Mild asthma	3	3
Smokers	4	3
Mean (SD) duration of disease (years)	3.8 (0.8)	3 (0.5)

Patients' demographic data

20 patients, seven men and 13 women (table), were selected from an outpatient population. The main inclusion criteria were perennial rhinoconjunctivitis and disease duration of at least 2 years. Sensitisations to allergens other than mites were excluded by skin tests and radioallergen sorbent tests (mites, grasses, parietaria plant, cat and dog dander, olive, birch, *Alternaria*, and *Aspergillus*). Six patients had mild intermittent asthma, but none of the patients had systemic immunological disease, major anatomical alterations of the upper airways, severe atopic dermatitis, were receiving chronic corticosteroid treatment, or had previously received immunotherapy. Pregnant or lactating women were excluded. Patients gave written informed consent.

Immunotherapy consisted of tablets of monomeric allergoid *Dermatophagoides pteronyssinus* and *D farinae* (LAIS, Laboratorio Farmaceutico Lofarma, Milan, Italy). The allergen was modified by reaction with potassium cyanate at neutral pH to substantially decrease, by a substitution of ϵ -amino groups of lysine residues, its capacity to react with IgE, as measured by radioallergen sorbent-test inhibition.¹⁶ About 84% of the ϵ -amino groups were substituted, whereas the molecular dimensions of the carbamylated allergen assessed by sodium dodecylsulphate-polyacrylamide gel electrophoresis remained unchanged. The immunotherapy preparation was titrated in allergenic units (AU) and standardised by radioallergen sorbent-test inhibition compared with an inhouse reference titration. We could not detect the content of major allergens because of the loss of activity due to the chemical treatment.¹⁶

The tablets were placed under the tongue, dissolved in the mouth for 1–2 min, and swallowed. The build-up phase involved the administration of increasing doses of the allergen (25 AU, 50 AU, 100 AU, 200 AU, 300 AU, 600 AU, and 1000 AU). Each dose was taken for 3 alternate days. In the maintenance phase, patients received 2000 AU twice weekly; the maintenance dose was about twenty times that used in conventional subcutaneous immunotherapy. The placebo tablets were identical to immunotherapy in flavour and appearance. During the course of the study, patients were allowed to take other drugs for relief of symptoms if needed: cetirizine or loratadine (10 mg tablet, once daily), beclomethasone nasal spray, inhaled salbutamol (250 μ g/puff, 1–3 puffs) on demand, and short courses of oral prednisone (25 mg/day for 3 days) in the case of severe rhinitis. Each patient was taking preventive environmental precautions against mites at enrolment.

We asked patients to keep a daily record of the presence and severity of: nasal obstruction, rhinorrhoea, nasal itching, sneezing, conjunctival itching and hyperaemia, palpebral oedema, asthma attacks, and cough. Symptoms were graded as: 0 absent, 1 mild, 2 moderate, and 3 severe.¹⁵ Each dose taken received a score of 4 points. Patients also recorded troublesome symptoms and were asked to contact our service if any discomfort occurred. We assessed compliance with treatment by tablet counts and collected diary cards at visits with intervals of no longer than 6 months.

Tests for allergen-specific conjunctival challenge¹² were done at enrolment (summer 1993) and during the summers of 1995, and 1996 (after 12 and 24 months of treatment). Patients discontinued any drug at least 15 days before each test. We used local anaesthetic (oxybuprocaine 4 mg/mL) into the conjunctival sacs, and took scrapings before the challenge. After scrapings, increased concentrations of allergen (lyophilised Der p 1, DHS-Bayropharm, Milan, reconstituted at three-fold dilutions) were placed on to the eyes until we saw a clinical reaction.¹² We assessed the clinical reaction according to an arbitrary scale (0 absent, 1 mild, 2 moderate, 3 severe), and included itching,

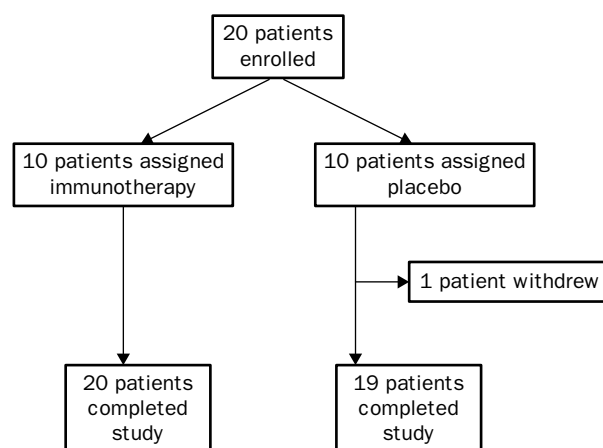


Figure 1: Trial profile

hyperaemia, lacrimation, and palpebral oedema. We took a dose eliciting a score of seven or more as the threshold dose and used that dose in later challenge tests. We investigated only the early-phase reaction. We took scrapings from the upper tarsal conjunctiva, which were transferred to glass slides, air-dried, and stained with May-Grunwald giemsa.¹² The numbers of neutrophils and eosinophils were expressed as mean number per ten fields in light microscopy for each sample.

We used an alkaline phosphatase-antialkaline phosphatase immunochemical method to test for expression of ICAM-1.¹⁷ Conjunctival scrapings were incubated with an ICAM-1 monoclonal antibody (1 mg/mL, 84H10, IgG1, Immunothec, Marseille, France) or anticytokeratin monoclonal antibody (DAKO, Milan, Italy). Samples were rinsed and incubated with rabbit antimouse IgG, followed by alkaline phosphatase-antialkaline phosphatase complexes. Finally, a substrate of basic new fuchsin, naphthol biphosphate, and levamisole (to inhibit endogenous phosphatase) were added. We counterstained all samples with Carazzi's haematoxylin and the ICAM-1 positivity was graded as follows: 0 no positive cells, 1 mild positivity on 25% of cells, 2 mild positivity on 75% of cells, 3 intense positivity on 75% of cells, and 4 intense positivity on all cells.

At enrolment and after 12 and 24 months of treatment, we measured serum concentrations of some inflammation-related mediators (eosinophil cationic protein, and soluble myeloperoxidase) by a double-antibody RIA with iodine-125-labelled species (MPO-RIA and ECP-RIA, Pharmacia, Uppsala, Sweden). The values were expressed as μ g/L through a six-point calibration curve.

Because symptom score, inflammatory-cell number, ICAM-1 positivity, and plasma mediator concentrations might have been non-normally distributed, we used Mann-Whitney *U* test for comparisons between groups and Wilcoxon's rank sum test for comparisons within groups, where appropriate.

Results

19 of 20 patients completed the study (figure 1). One patient from the placebo group withdrew during the first year because of poor compliance with visits and filling the diary card; we excluded this patient from the final analysis. The remaining patients completed the study.

We found a seasonal trend in symptom scores (figure 2). Allergen exposure was greater and symptoms were more severe in both groups during the winter months. From March to October, 1994, the placebo group had lower scores ($p=0.01$), whereas from November, 1994, to September, 1995, the immunotherapy group had lower scores ($p<0.0002$).

Minimum persistent inflammation was present in symptom-free patients even without allergen-specific

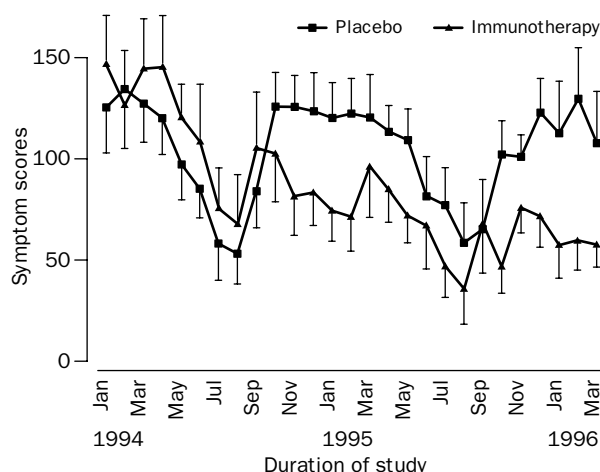


Figure 2: **Mean (95% CI) symptom scores in the immunotherapy (n=10) and placebo (n=9) groups**

conjunctival challenge as shown by the presence of some neutrophils in the prechallenge conjunctival scrapings. In the immunotherapy group there were significant decreases in the background neutrophilic infiltration (from 12 months to 24 months $p=0.01$; from enrolment to 24 months $p=0.002$). Similarly, the immunotherapy group showed significant decreases in the number of neutrophils in postchallenge scrapings (from enrolment to 12 months $p=0.02$; from enrolment to 24 months $p=0.004$; from 12 months to 24 months $p=0.004$). We found no change in neutrophil number in the placebo group. Eosinophilic infiltration decreased significantly in the immunotherapy group before challenge (from enrolment to 12 months $p=0.05$; from 12 months to 24 months $p=0.01$; from enrolment to 24 months $p=0.001$). There was a significant reduction in eosinophils in the placebo group after challenge (from enrolment to 24 months $p=0.05$).

Immunotherapy led to a reduction in ICAM-1 expression before challenge (from enrolment to 24 months $p=0.01$; from 12 to 24 months $p=0.05$) and during and after treatment (from enrolment to 12 months $p=0.03$; from enrolment to 24 months $p=0.002$; from 12 to 24 months $p=0.01$). Results of analyses between groups are shown in figure 3.

We found a significant decrease in eosinophil cationic protein in the immunotherapy group after 12 months of treatment ($p=0.04$), whereas there was no difference between 12 and 24 months of treatment (12 months $25.7 \mu\text{g/L}$ [SD 10] months, 24 months $31.2 \mu\text{g/L}$ [17], $p>0.05$); we saw no changes in the placebo group. Between-group comparison showed a significant difference after 12 months (placebo $54.1 \mu\text{g/L}$ [17] *vs* immunotherapy $25.7 \mu\text{g/L}$ [10]; $p=0.01$) and 24 months (placebo $56 \mu\text{g/L}$ [24] *vs* immunotherapy 31.2 [9]; $p=0.04$). We also found a significant decrease in myeloperoxidase in the immunotherapy group after 12 months (enrolment $627 \mu\text{g/L}$ [181] *vs* 12 months $474 \mu\text{g/L}$ [123]; $p=0.05$); at this time we found a significant between-group difference (placebo $665 \mu\text{g/L}$ [170] *vs* immunotherapy $474 \mu\text{g/L}$ [123]; $p=0.05$).

The treatment was well tolerated. Three patients experienced side-effects: one patient in the immunotherapy group had oral itching while taking the maintenance dose, and in the placebo group one patient had rhinitis (onset 1 h after taking drug) and one had oral

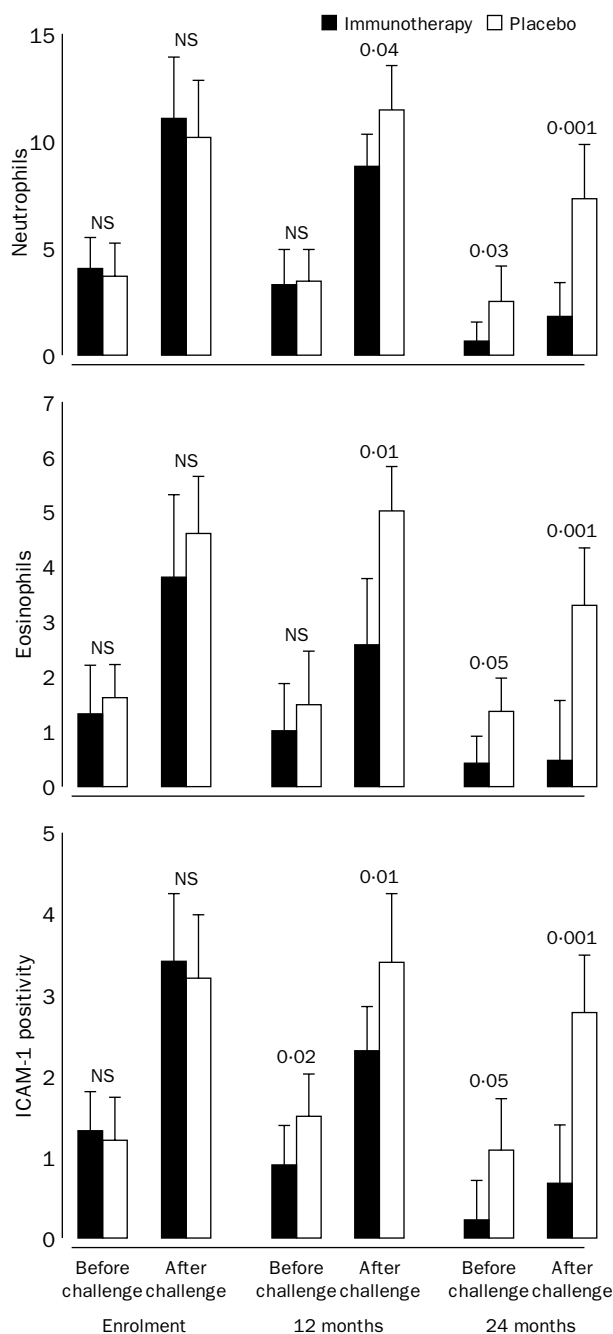


Figure 3: **Inflammatory conjunctival variables (mean [95% CI] before and after challenge at enrolment, 12 months, and 24 months**

itching during the build-up phase. These side-effects disappeared within a few minutes and required no pharmacological treatment or dosage adjustment. No other side-effects were seen during the study.

Discussion

Several experimental data on the effects of subcutaneous immunotherapy on immunological variables show a reduction of inflammatory cells and mediators in target organs.¹⁸⁻²⁰ Nasal immunotherapy also seems to reduce allergic inflammation in the nose,¹⁵ whereas no such effect has been seen for oral routes. Based on preliminary kinetic data obtained in healthy humans,¹¹ the sublingual/oral route seems to be the most effective. In

fact, a relevant part of the allergen stayed in the mouth for a long period after the tablet was held under the tongue, whereas the swallowed fraction of the allergen was quickly absorbed. Therefore, in sublingual administration all the oral mucosa are likely to adsorb molecules.

The use of allergen-specific nasal and conjunctival challenges is safe and reliable and allowed us to obtain important information about the kinetic response of the target organ to allergenic challenge.^{12,13} We were also able to see early and a late inflammatory nasal and conjunctival responses, which involved eosinophilic and neutrophilic infiltration and the expression of ICAM-1 on the epithelium. Furthermore, we found evidence of minimum nasal and conjunctival persistent inflammation in symptom-free allergic patients, constantly exposed to allergens.¹⁴ The events in the eyes and the nose are similar to those in the bronchi and are highly reproducible in allergic patients, irrespective of the organ involved. Therefore, we chose allergen-specific conjunctival challenge to measure the effects of specific immunotherapy. The effects of the treatment on the minimum persistent inflammation and cellular-molecular events were significant after allergen challenge. In particular, we found a reduction of cellular infiltration and ICAM-1 expression on epithelial cells. These observations are consistent with other results, which show that specific immunotherapy can decrease allergen-driven inflammatory phenomena. Furthermore, the effects of immunotherapy of allergic inflammation in our study parallel those described in other models that used different variables.¹⁸⁻²⁰ The symptom reduction remains the main measurement of immunotherapy effectiveness,² and our scores confirmed the clinical efficacy of this kind of immunotherapy, with constant and significant clinical improvement. As previously described, the side-effects were negligible, and all patients showed good compliance with treatment.¹⁵

This form of allergen-specific immunotherapy is effective and might be valuable in the treatment of respiratory allergy, but larger numbers of patients need to be investigated in trials.

Contributors

G Passalacqua was responsible for the overall planning, supervision, and writing. M Albano and L Fregonese carried out the clinical study and did the conjunctival challenges. C Pronzato and A Riccio carried out the laboratory tests. G S Mela did the statistical analysis. G W Canonica was the coordinator of the study and contributed to planning the trial and writing the manuscript.

Acknowledgments

We thank Lofarma, Milan, Italy, for providing the immunotherapy tablets. Supported by ARMIA (Associazione Ricerca sulle Malattie Immunologiche e Allergiche); CNR SP2 FATMA (5710) grant to GWC; CNR Target Project Ingegneria Genetica (910018) grant to MB; and Italian Ministry of University and Science and Technological Research grant to GWC.

References

- 1 Passalacqua G, Canonica GW. Alternative routes for allergen specific immunotherapy. *J Invest Allergol Clin Immunol* 1996; **6**: 81-87.
- 2 Malling HJ, Weeke B. EAACI Immunotherapy position paper. *Allergy* 1993; **48**: 1-81.
- 3 Tari MG, Mancino M, Monti G. Efficacy of sublingual immunotherapy in patients with rhinitis and asthma due to house dust mite: a double blind study. *Allergol Immunopathol* 1990; **18**: 277-84.
- 4 Feliziani V, Lattuada G, Parmiani S, Dall'Aglio PP. Safety and efficacy of sublingual rush immunotherapy with grass allergen extracts: a double blind study. *Allergol Immunopathol* 1995; **23**: 173-78.
- 5 Sabbah A, Hassoun S, Le Sellin J, Andre C, Sicard H. A double blind placebo controlled trial by the sublingual route of immunotherapy with a standardized grass pollen extract. *Allergy* 1994; **49**: 309-13.
- 6 Troise C, Voltolini S, Canessa A, Pecora S, Negrini AC. Sublingual immunotherapy in parietaria pollen induced rhinitis: a double blind study. *J Invest Allergol Clin Immunol* 1995; **5**: 25-30.
- 7 Giovane A, Bardare M, Passalacqua G, et al. A three year double blind placebo-controlled study with specific oral immunotherapy to Dermatophagoides: evidence of safety and efficacy in pediatric patients. *Clin Exp Allergy* 1994; **24**: 53-59.
- 8 Cooper PJ, Darbyshire J, Nunn AJ, Warner JO. A controlled trial of oral hyposensitization in pollen asthma and rhinitis in children. *Clin Allergy* 1984; **14**: 541-50.
- 9 Taudorf E, Lanner A, Laursen L, Bjorksten B, Dreborg S, Weeke B. Specific IgG IgE and IgA antibody response to oral immunotherapy in birth pollenosis. *J Allergy Clin Immunol* 1989; **83**: 589-94.
- 10 Holt PG. A potential vaccine strategy for asthma and allied atopic diseases during childhood. *Lancet* 1994; **344**: 456-58.
- 11 Bagnasco M, Mariani G, Passalacqua G, et al. Absorption and distribution kinetics of the major Parietaria judaica allergen (Par j 1) administered by noninjectable routes to healthy human beings. *J Allergy Clin Immunol* 1997; **100**: 121-29.
- 12 Ciprandi G, Buscaglia S, Pesce GP, Villaggio B, Bagnasco M, Canonica GW. Allergic subjects express ICAM-1 on epithelial cells of conjunctiva after allergen challenge. *J Allergy Clin Immunol* 1993; **91**: 783-92.
- 13 Ciprandi G, Pronzato C, Ricca V, Passalacqua G, Bagnasco M, Canonica GW. Allergen specific challenge induces ICAM1 expression on nasal epithelial cells in allergic subjects: relationships with early and late phase events. *Am Rev Respir Dis* 1994; **150**: 1653-59.
- 14 Ciprandi G, Buscaglia S, Pesce GP, et al. Minimal persistent inflammation is present at mucosal level in asymptomatic rhinitic patients with allergy due to mites. *J Allergy Clin Immunol* 1995; **96**: 971-79.
- 15 Passalacqua G, Albano M, Ruffoni S, et al. Local nasal immunotherapy to parietaria: evidence of reduction of allergic inflammation. *Am J Respir Crit Care Med* 1995; **152**: 461-66.
- 16 Mistrello G, Brenna O, Roncarolo D, Zanoni D, Gentili M, Falagiani P. Monomeric chemically modified allergens: immunologic and physicochemical characterization. *Allergy* 1996; **51**: 8-15.
- 17 Cordell JL, Falini B, Erber WN, et al. Immunoenzymatic labelling of monoclonal antibodies using immunocomplexes of alkaline phosphatase and monoclonal anti alkaline phosphatase (APAAP complexes). *J Histochem Cytochem* 1984; **32**: 219-45.
- 18 Hamid QA, Schotman E, Jacobson RM, Walker SM, Durham SR. Increases in interleukin 12 messenger RNA+ cells accompany inhibition of allergen-induced late skin responses after successful grass pollen immunotherapy. *J Allergy Clin Immunol* 1997; **99**: 254-60.
- 19 Rak S, Hakanson L, Venge P. Immunotherapy abrogates the generation of eosinophil and neutrophil chemotactic activity. *J Allergy Clin Immunol* 1990; **86**: 706-11.
- 20 Secrist H, Chelen CJ, Wen Y, Marshall JD, Umetsu DT. Allergen immunotherapy decreases interleukin 4 production in CD4+ T cells from allergic individuals. *J Exp Med* 1993; **178**: 2123-30.